

## INTRODUCTION

Corneal ectasias cause decreased vision from irregular astigmatism that often has limited correction with traditional glasses or soft contact lenses. Hard contact lenses such as corneal or scleral gas permeable contact lenses often provide the best visual benefit for these patients. However, there are complications associated with these conditions that are visually devastating even with these hard lenses, especially if they occur within the visual axis. These complications often require surgical intervention.

Acute corneal hydrops, a complication of advanced keratoconus, occurs because the integrity of Descemet's membrane is compromised. Aqueous humor is then taken up by the stroma, causing significant corneal edema and sudden, painful loss of vision. This can cause permanent decreased vision from scarring, prolonged edema, and neovascularization. Often, following hydrops, patients are left with corneas that are so scarred, the best option for good vision is a corneal transplant. Large diameter gas permeable scleral lenses could provide improved vision, saving patients from invasive surgeries and potential transplant rejection.

## CASE HISTORY

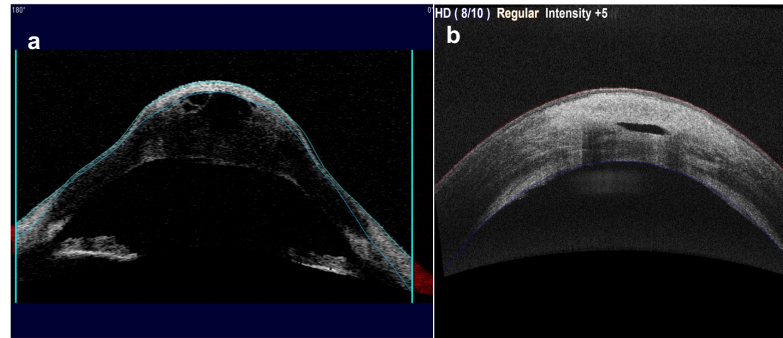
A 22-year-old white male presented for corneal cross-linking consultation after recent diagnosis of keratoconus. Three days following, he presented with acute corneal hydrops with an OCT pachymetry measurement of over 800um. He was managed to resolution and brought to specialty contact lens service. His BCVA with most recent spectacles was 20/400 OD and CF @ 2 ft OS. Ocular examination shows classic signs of advanced keratoconus and previous hydrops. Corneal signs included significant central stromal and endothelial scarring OS-OD within the visual axis, apical thinning, Vogt striae, Munson's sign, and Fleisher ring. The plan was to fit with a scleral contact lens in his left eye to assess for best correctable visual acuity prior to transplant consideration. Lens will be held off OD until after CXL procedure.

## LENS FITTING

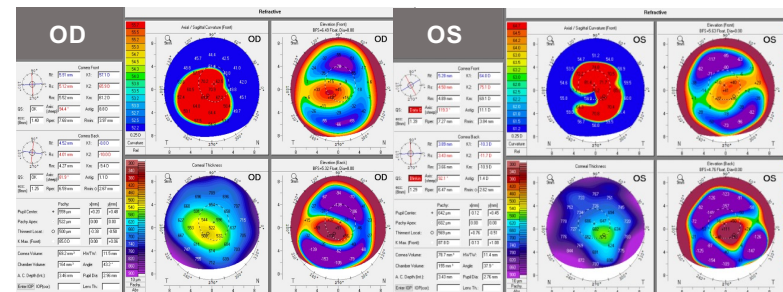
Visit	Lens Parameters	Assessment	VA	Plan/Order
Initial Fit	OS: -3.00D [oblate] DIA 15.8 SAG 4780 / BC 7.67 Limb curve +4 / scleral landing +3/-4	200 microns clearance (+)limbal clearance Moderate heel down blanching in periphery	20/70 OR -3.25D → 20/25-	Order -6.25D lens with increase sag by 200um, flatten limbal curve to +6
OS Dispense	OS: -6.25D [oblate] DIA 15.8 SAG 4980 / BC 7.67 Limb curve +6 / Scleral landing +3/-4	300 microns clearance, excessive superior limbal curve to +8 (+)limbal clearance Moderate heel down in periphery, excessive movement	20/30 OR pl sph → 20/30+	Order flattened limbal curve to +8 to combat sup/inf blanching & movement

Reported monocular diplopia from lens at dispense that does not improve with spherocylindrical OR, increasing the OZD as large as possible should result in improvement. He reported excellent comfort, and ease at handling lens. At follow-up he complained of lens fogging which comes and goes and lasts a few hours.

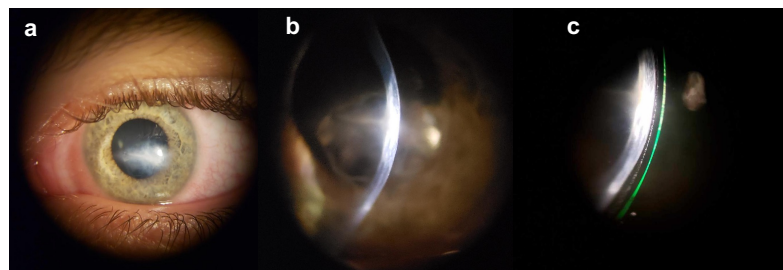
Visit	Lens Parameters	Assessment	VA	Plan
OS Final Lens	OS: -6.25D [oblate] DIA 15.8 SAG 4980 / BC 7.67 Limb curve +8 / Scleral landing +3/-4	300 um central clearance (+) limbal clearance well centered with mild movement. Stain after lens removal shows epithelial bogging and SPK	20/25- OR pl sph → 20/25-	Increase sag by 75um, Flatten limbal curve by 1 step, Schedule CXL OD



**FIGURE 1:** Anterior segment OCT of (a) acute corneal hydrops OS at presentation with pachymetry measurements of >800um and (b) Corneal hydrops near resolution, slight residual edema and notable scarring.



**FIGURE 2:** Pentacam scans of the right and left eye prior to contact lens fit.  
OD: Steep K 65.9D; Flat K 57.1D  
OS: Steep K 75.1D; Flat K 64.0D



**FIGURE 3:** Anterior segment photographs of eye on contact lens follow-up. (a) Corneal scarring in the central cornea OS, (b) optic section of residual edema and scarring OS, (c) Scleral lens post >3 hours settling, noted tear debris in the tear lens and fluorescein on anterior tear film

## ACKNOWLEDGEMENTS & REFERENCES

Special thanks to Dr. Nicholas Gidosh & The Eye Institute's Cornea and Specialty Contact Lens Service at Salus University  
References Available upon request

## DISCUSSION

As of this point, a final lens in the fitting of the left eye has been reached with a result of BCVA to 20/25-. Following CXL OD, a scleral lens will be fit to best corrected visual acuity. The right scleral lens fit was delayed because corneal cross linking is known to cause a reduction in corneal keratometry, and therefore change the fit of the scleral lens. Following scleral lens fitting OS, the end point visual acuity of 20/25<sup>-2</sup>, the patient was saved from the need of corneal transplantation.

Acute corneal hydrops is noted as an uncommon complication of corneal ectasias with an incidence between 0.2 and 2.8%. With the resolution of acute corneal hydrops, patients maintain a scar which can cause poor vision from light scattering, it can also flatten the cornea and subsequently improve vision for some so long as the sustained scarring is outside of the visual axis. If the scarring is sustained within the visual axis, corneal transplant may be the only option for good vision. A last resort management for corneal ectasia is corneal transplantation using penetrating keratoplasty (PKP)/deep anterior lamellar keratoplasty (DALK). Previous studies show that approximately 60% of patients with keratoconus require penetrating keratoplasty to achieve functional vision following acute corneal hydrops. Full thickness corneal transplants are known to last for at most 20 years. For this patient at 22, assuming he lives to be 80, he may sustain at minimum 3 corneal surgeries to maintain the integrity of the cornea. This would not include any surgeries or complications he may sustain from potential transplant rejection.

Hard contact lenses should be utilized prior to corneal transplant consideration. This patient was fit with an oblate design scleral contact lens which provided good comfort and a regular anterior surface for adequate vision. He achieved a new best corrected visual acuity to 20/25 in scleral contact lenses, better than pre-hydrops visual acuity of 20/60 OD and 20/150 OS. In the end, the decision to pursue transplant vs hard contact lens as first line treatment should remain a discussion between the patient and doctor

## CONCLUSION

Early diagnosis of keratoconus is imperative for prompt disease halting interventions such as corneal cross-linking. These procedures prevent the further progression to advanced disease. Advanced keratoconus often yields complications which leave the patient with severe scarring, increased corneal irregularity, and haze, like the patient presented in this case. These outcomes often cause decreased vision that are difficult to correct with traditional spherocylindrical glasses and/or specialty gas permeable contact lenses. These complications that cause severely decreased vision result in the need for surgical interventions such as penetrating keratoplasty to provide a clearer and more regular refracting surface. These interventions come with the risk of transplant rejection or recurrent corneal ectasia, and then require a second corneal transplant.

This patient experienced severe acute corneal hydrops which left him with scarring across the central cornea which made traditional glasses and soft contact lenses inadequate for good vision. An oblate scleral lens provided near perfect vision (BCVA 20/25) so that the need for corneal transplant could be postponed. This saves him from surgical complications at the present time. These lenses provide longevity to the natural cornea and quality vision without putting him under the knife.