

The Therapeutic Effects of Scleral Lenses in Patients Post Mohs Surgery with Exposure Keratitis: a Mini Case Series

Marsha Zaman BS, Stacy Zubkousky O.D. FAAO FSLs, Wateen Alami BS, Crystal Victor O.D., Thuy- Lan Nguyen O.D.FAAO FSLs

INTRODUCTION

Exposure keratopathy occurs from decreased ocular surface lubrication due to inadequate eyelid closure.¹ In patients undergoing Mohs surgery, a procedure involving resecting cancer-laden cells of the skin, lid malposition can be an unintended consequence. This mini-case series evaluates the therapeutic effects of scleral lenses to protect corneal tissue from damaging environmental factors by acting as a physical barrier and supplementing lubrication to mitigate symptoms of exposure keratopathy.

CASE DESCRIPTION

Patient A is a 70-year-old white female s/p Mohs surgery OS and Blepharoplasty OU presenting for a contact lens fitting OU. She reports chronic redness and pain secondary to dry eye OU. Her current dry eye regimen consists of moisture chamber goggles, preservative free artificial tears PRN, punctal plugs, gel lubricating ointment and warm compresses. Clinical findings are as follows:

BCVA: OD 20/25-1 OS 20/25

Anterior segment evaluation findings:

- 4mm Lagophthalmos OU
- 3+ diffuse bulbar injection OU
- 3+ confluent PEK inferiorly with neovascularization extending 0.5mm OD
- 4+ inferior confluent PEK with neovascularization and pannus extending 1.5mm OS.

Patient B is an 80-year-old white male s/p Mohs surgery OD and multiple reconstructive surgeries OD, presenting for contact lens fitting OD. He reports blurry vision and chronic dry eye OU.

Clinical findings are as follows:

BCVA: OD 20/70, OS 20/25

Anterior segment evaluation findings:

- Ectropion OD
- Lagophthalmos OU
- 3+ diffuse bulbar injection OD
- Pannus and neovascularization present 360 degrees extending 5mm into the cornea
- Geographical area of corneal stromal thinning was present inferiorly and superior nasally OD
- 4+ coalesced PEK with unstable tear film and mucous strands OD

CONTACT LENS SELECTION

The most common indications of scleral lens therapy include ocular surface disease and exposure keratopathy.² Based on the severity of dry eye and the degree of symptoms experienced, both patients were fit with scleral lenses. Modifications of lens design were necessary in order to obtain appropriate fit, comfort and clarity of vision.

Patient A was fit with an 18.0mm scleral lens in Optimum Infinite material with Hydrapeg coating. This lens was chosen in order to compensate for the patient’s significant conjunctival involvement.

Patient B was fit with a 15.6mm scleral lens in Optimum Infinite material with plasma treatment. An 18.0mm scleral lens was initially proposed for patient B as he had similar extent of involvement as patient A; however due to patient’s hesitation of handling a larger diameter lens, a 15.6mm lens was chosen.

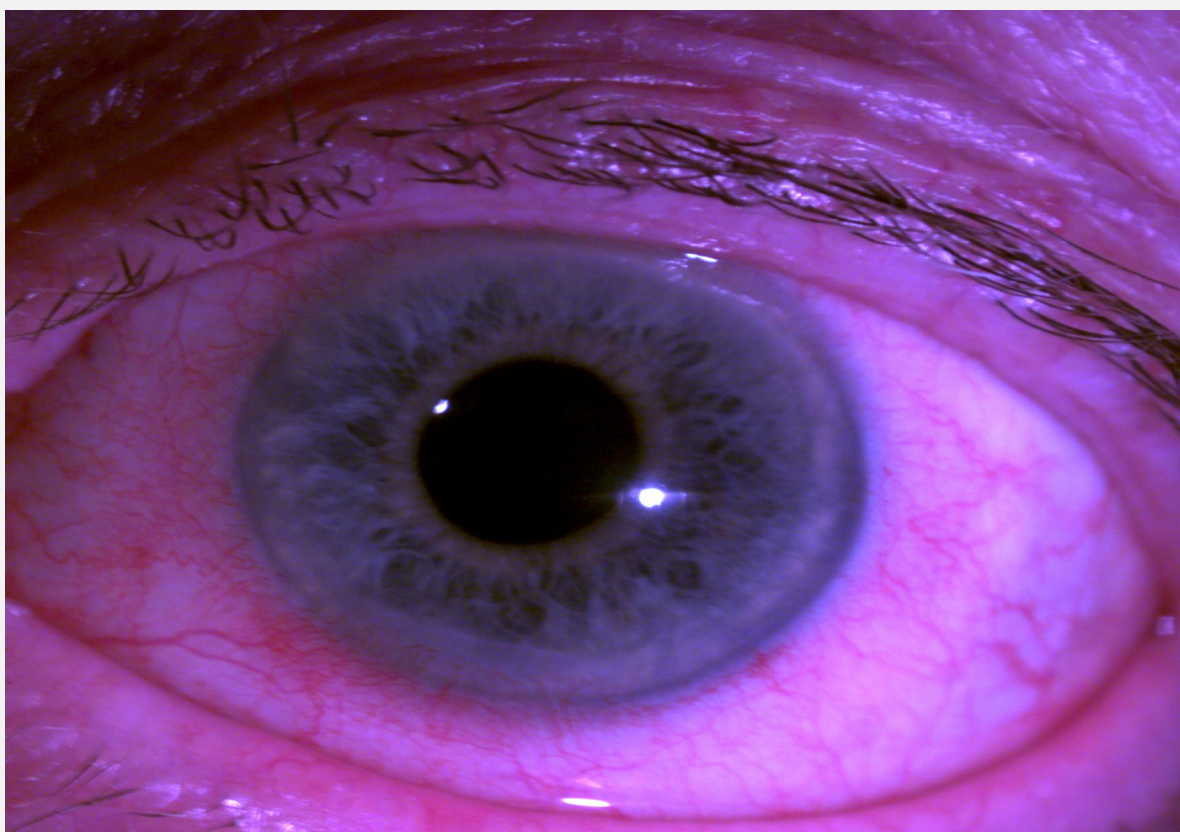


Figure 1: Baseline anterior segment photo of patient A OS displaying diffuse bulbar injection and neovascularization of the cornea

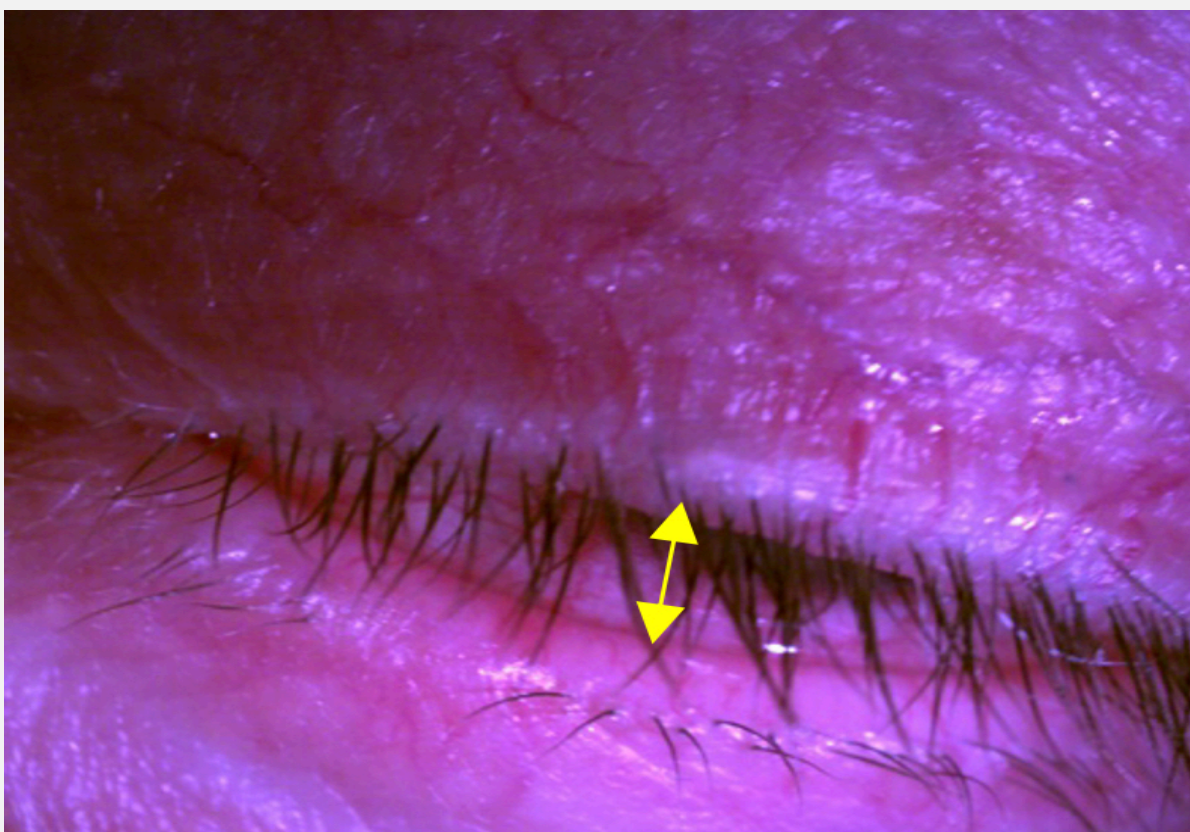


Figure 2: Baseline anterior segment photo of patient A displaying lagophthalmos OS

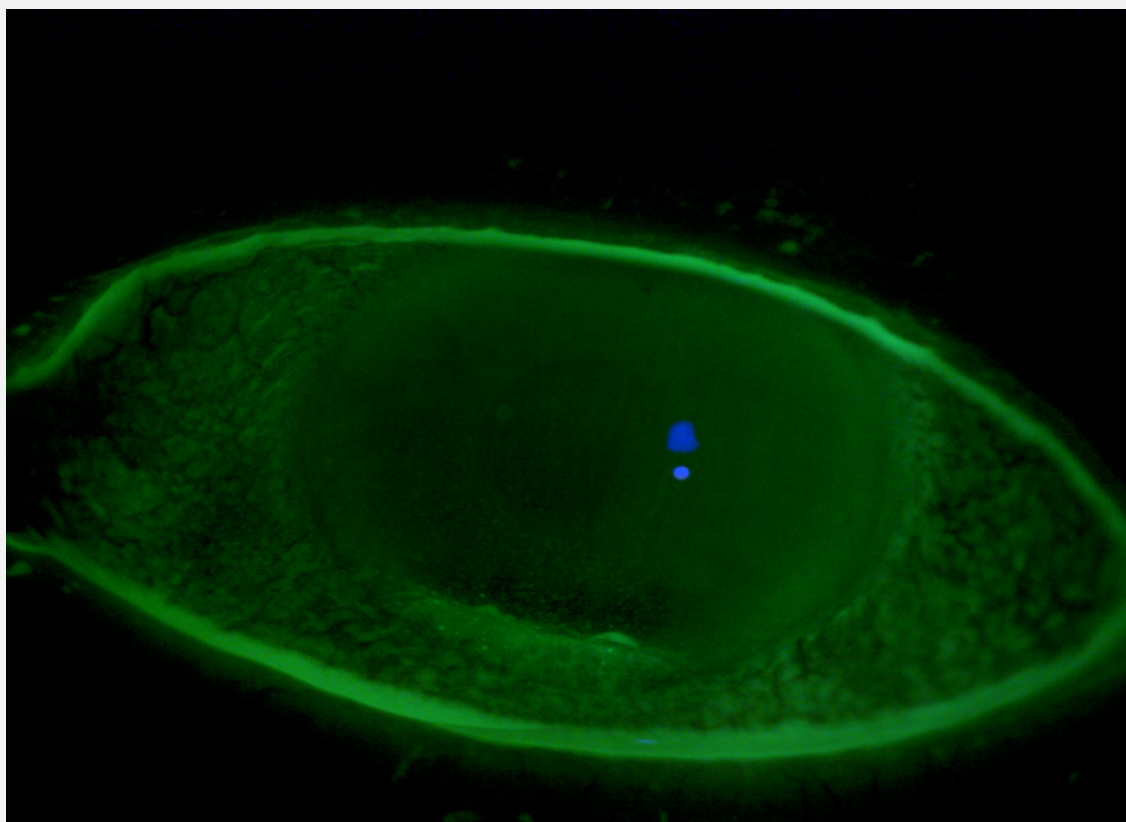


Figure 3: Baseline anterior segment photo of patient A OS stained with sodium fluorescein showing significant dryness of cornea and conjunctiva

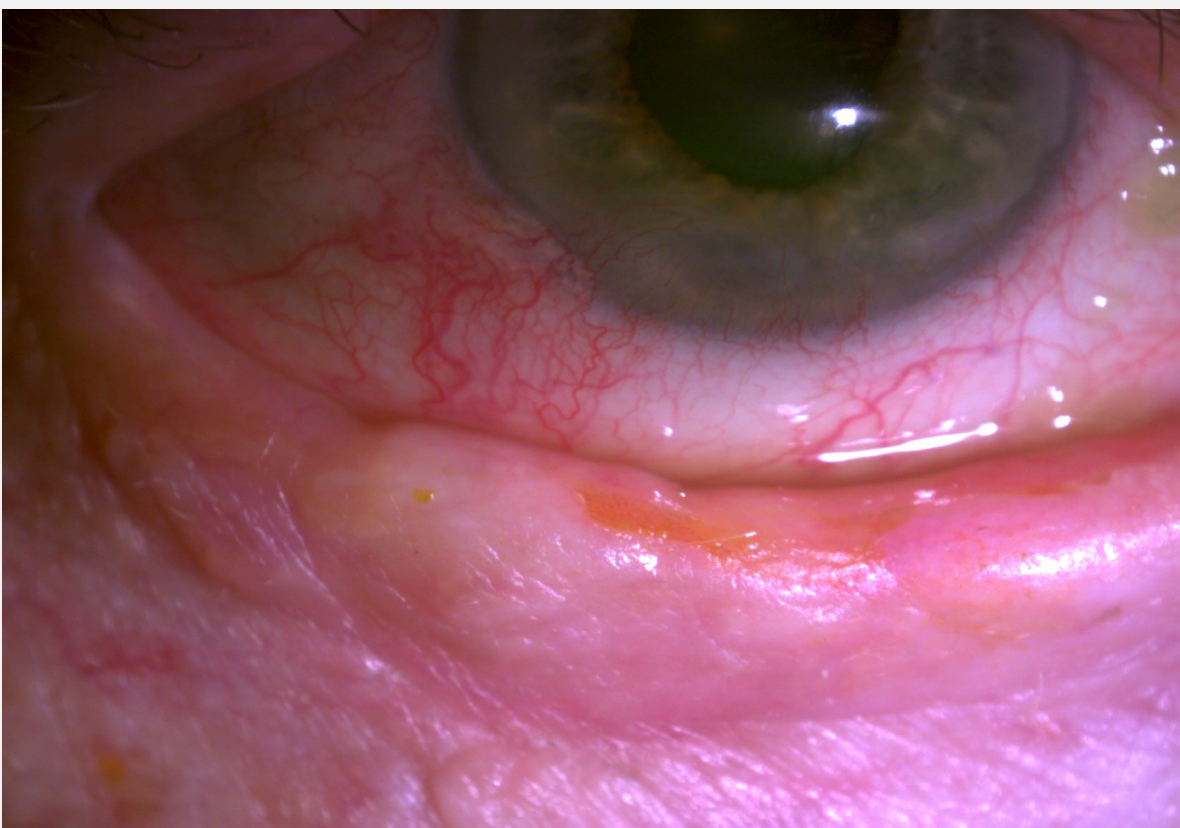


Figure 4: Baseline anterior segment photo of patient B OD displaying ectropion, neovascularization of the cornea and bulbar injection

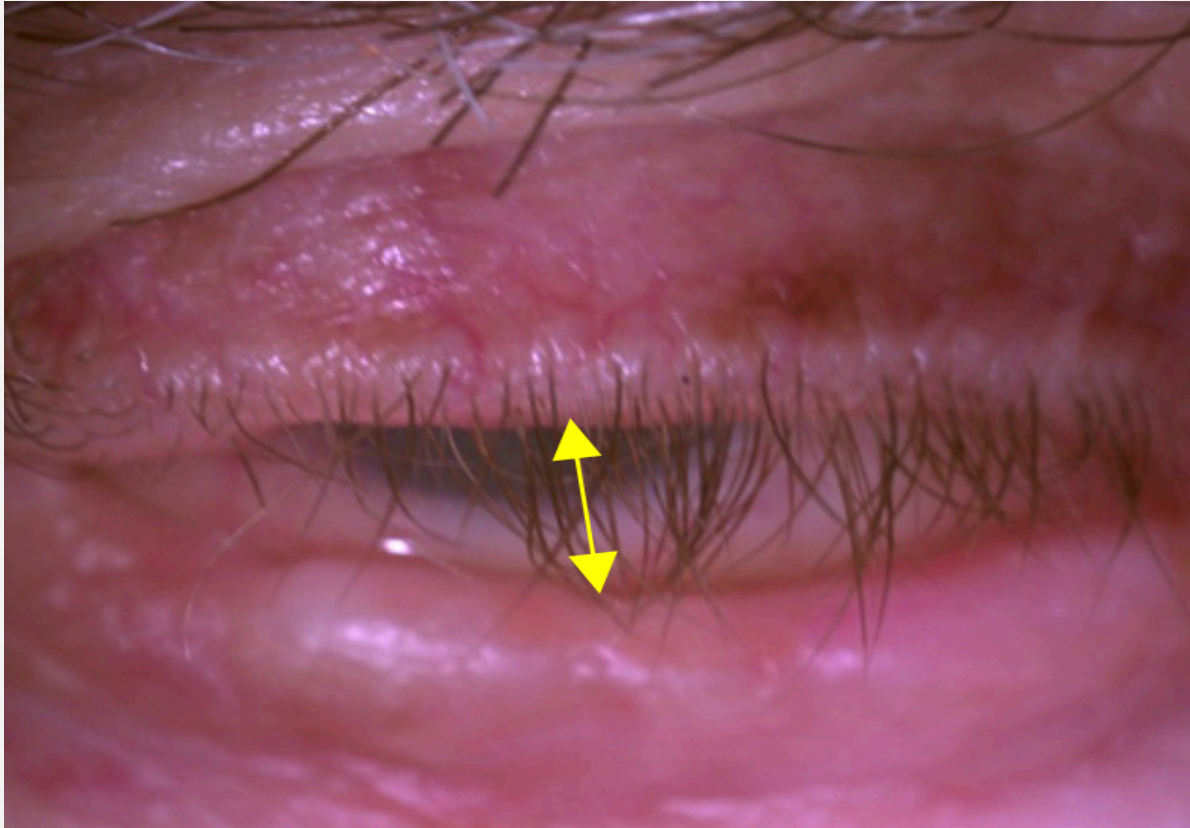


Figure 5: Baseline anterior segment photo of patient B illustrating lagophthalmos OD

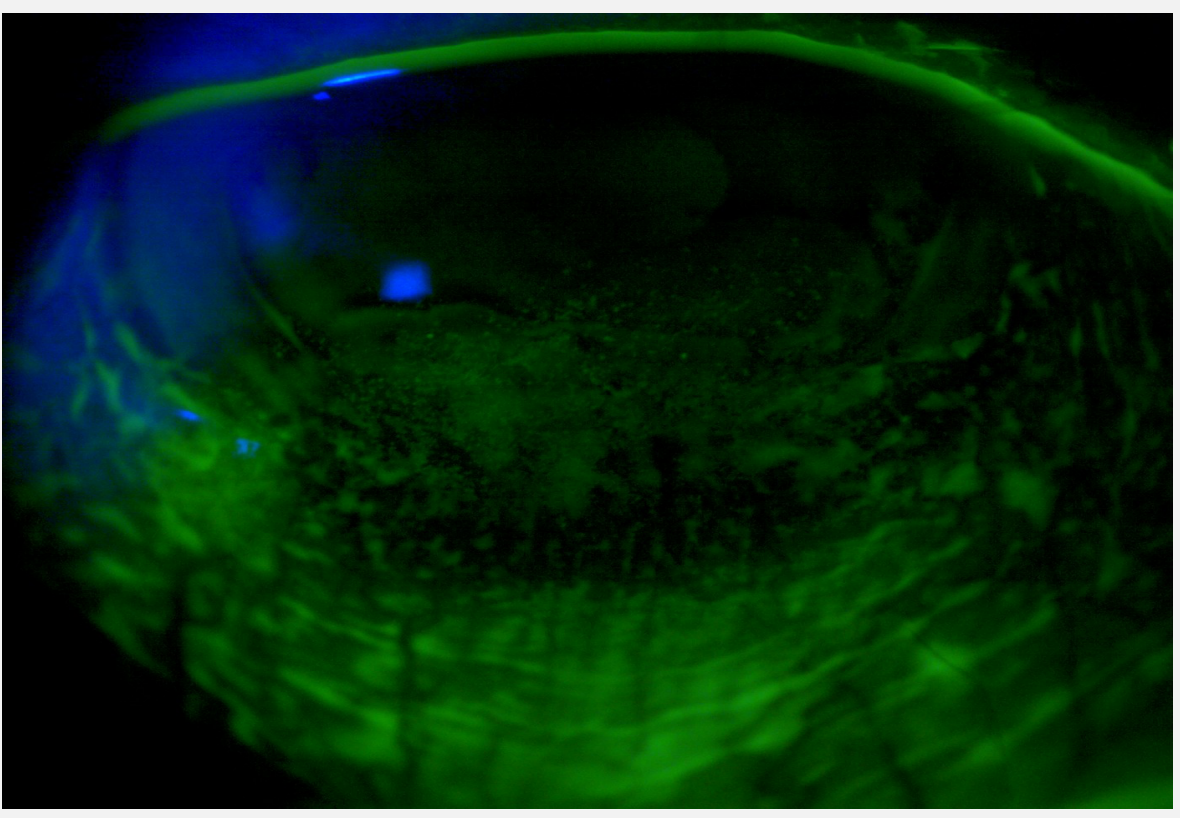


Figure 6: Baseline anterior segment photo of patient B stained with sodium fluorescein showing significant dryness of cornea and inferior conjunctiva

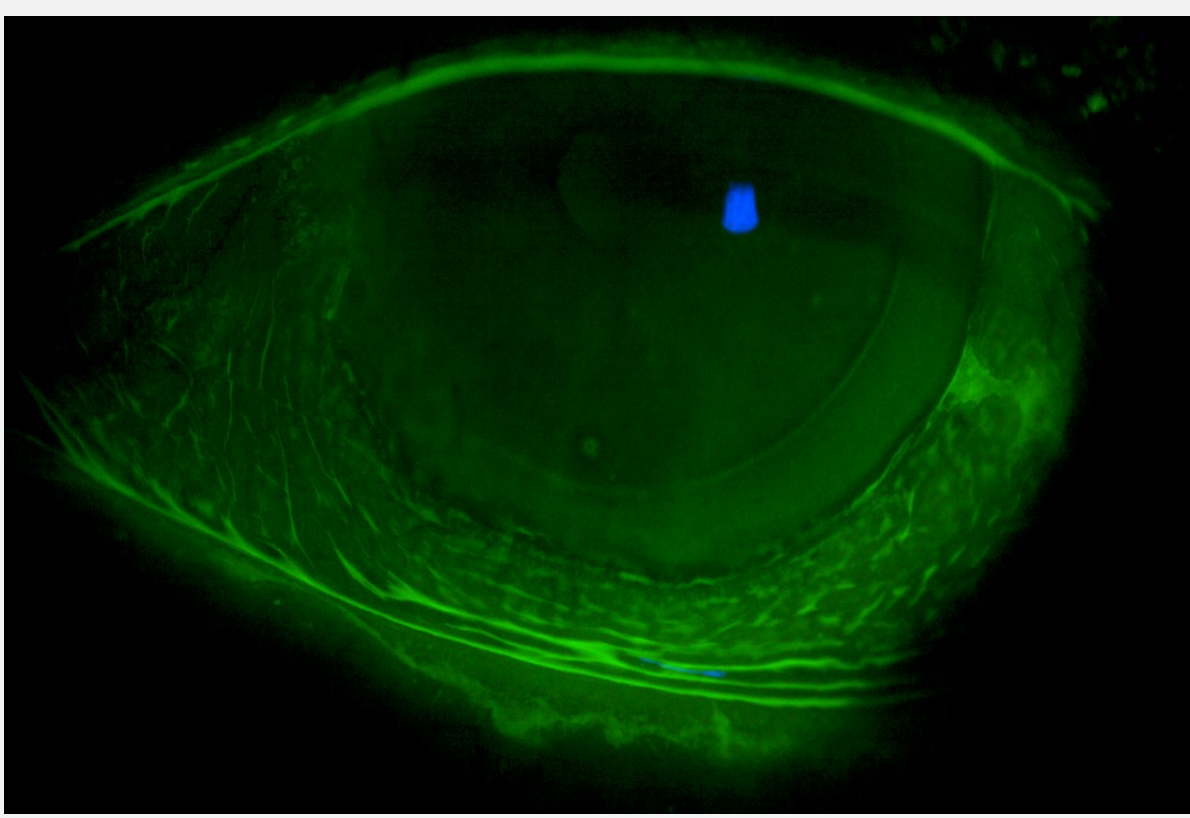


Figure 7: Anterior segment photo of patient B stained with sodium fluorescein illustrating improvement of staining in the cornea and conjunctiva OD

FINAL CONTACT LENS PARAMETERS

Patient A Final Lens Parameters:

Eye	VA	Power	Diameter	Treatment	Sag	Material	Color
OD	20/25+	+0.51-1.02x111	18.00mm	HydraPeg	2050	Optimum Infinite	Clear
OS	20/25+	+2.06-2.88x083	18.00mm	HydraPeg	1900	Optimum Infinite	Blue

Patient B Final Lens Parameters:

Eye	VA	Power	Diameter	Treatment	Sag	Material	Color	SC-R	IC-R	PC-R
OD	20/50	+4.75D	15.60mm	Plasma	4150	Optimum Infinite	Clear	STD	M	STD L +75/-125

DISCUSSION

Basal Cell Carcinoma (BCC) is a locally invasive malignant skin tumor which predominantly affects the sun-exposed areas of the head and neck with some cases involving the epidermis around the orbits.³ For high-risk facial lesions and recurrent BCC, Mohs micrographic surgery (MMS), a technique that combines staged resection with comprehensive surgical margin examination, is the mainstay treatment.⁴ However, due to the anatomical location of periocular cutaneous malignancies, treatment from MMS can lead to a myriad of lower and upper eyelid complications including but not limited to cicatricial ectropion, cicatricial entropion, lagophthalmos, and lateral canthal disruption. These complications can lead to reconstructive procedures from which downstream effects such as eyelid laxity can predispose the patient to eyelid retraction, exposure keratopathy, and conjunctival irritation.⁵

Considerations for successful fitting of scleral lenses for ocular surface disease include fitting larger diameter lenses for coverage of the cornea as well as the conjunctiva. The use of high Dk material is also recommended to increase oxygen permeability to the often fragile tissue. In addition, Hydrapeg coating increases the lens wettability. Fitting the lenses looser or adding channels, which are grooves worked onto the back surface of the lens, promotes tear exchange.⁶

Both patients experienced significant clinical improvement and improvement of symptoms stemming from their exposure keratopathy. Patient A improved from 3+ to 2+ conjunctival injection in her left eye. PEK improved to 2+ after initially being documented as 3+ inferiorly. Patient B returned for a follow up after wearing the lenses for two months, and the conjunctival injection improved from 3+ to 1+ while his PEK inferiorly improved from 4+ to 2+. However, due to limitations of the wearing schedule of lenses up to 12 hours daily, adjunctive dry eye treatments such as using artificial tears, gel tears, moisture chamber goggles, and eye masks at nighttime are imperative in order to maintain the therapeutic effects. These cases further highlight the importance of co-management with oculoplastic specialists.

CONCLUSION

Post Mohs surgery patients can experience chronic discomfort from exposure keratopathy, yet there are limited forms of successful treatment. Scleral lenses were a compelling option considering the history of unsuccessful treatment with traditional dry eye therapies experienced by our patient. This mini-case series demonstrates the therapeutic benefits of scleral lenses. The fluid-ventilated design allows an oxygenated liquid reservoir to maintain continuous corneal hydration with no corneal touch. This improves comfort, vision, and ocular health in post Mohs surgery patients suffering from exposure keratopathy.⁷

REFERENCES

1. Management of exposure keratopathy. American Academy of Ophthalmology. (2016, May 4). Retrieved November 16, 2022, from <https://www.aao.org/eye/article/management-of-exposure-keratopathy-2>
2. Schornack, M. M., Pyle, J., & Patel, S. V. (2014). Scleral lenses in the management of ocular surface disease. *Ophthalmology*, 121(7), 1398–1405. <https://doi.org/10.1016/j.optha.2014.01.028>
3. Telfer, N.R., et al. "Guidelines for the Management of Basal Cell Carcinoma." *British Journal of Dermatology* - Wiley Online Library, <https://onlinelibrary.wiley.com/doi/full/10.1111/j.1365-2133.2008.08666.x>.
4. Kim, Dennis. "Basal Cell Carcinoma Review." *ClinicalKey.com*, Elsevier, 2020, www.clinicalkey.com/#.
5. Carniciu, Anais L., et al. "Eyelid Complications Associated with Surgery for Periocular Cutaneous Malignancies." *Facial Plastic Surgery*, vol. 36, no. 02, Apr. 2020, pp. 166–175, 10.1055/s-0040-1709515. Accessed 10 Dec. 2020
6. Pullum, K., & Buckley, R. (2007). Therapeutic and ocular surface indications for scleral contact lenses. *The Ocular Surface*, 5(1), 40–49. [https://doi.org/10.1016/s1542-0124\(12\)70051-4](https://doi.org/10.1016/s1542-0124(12)70051-4)
7. Harthan JS, Shorter E. Therapeutic uses of scleral contact lenses for ocular surface disease: patient selection and special considerations. *Clin Optom (Auckl)*. 2018;10:65-74.