



Highs and Lows: Scleral Lens Fitting on a Patient with Severe Keratoconus and Post-Penetrating Keratoplasty

Janna Pham and Karen Lee OD, FAAO, FSLs

Introduction

Scleral lenses (SL) are large-diameter gas permeable (GP) lenses that vault the cornea and rest on the sclera. High refractive error, ocular surface disease and irregular corneas are reasons to consider fitting a SL. Outcomes are generally positive giving patients sharper vision with improved lens comfort. Practitioners should take special precautions when fitting a SL on post-penetrating keratoplasty (PKP) eyes where risks of corneal edema, graft rejection and failure are more prevalent.¹ However, recent studies suggest increasing the lens oxygen permeability over a Dk of 100 Fatt provided no further reduction in corneal edema in healthy eyes.^{2,3} Practitioners without corneo-scleral topography can decrease chair time with a toric landing zone SL fitting set that works for both oblate and prolate corneas.

Case Presentation

VISIT 1:

57-year-old Hispanic female presents for a new contact lens fitting

Chief complaint: poor vision when wearing traditional small diameter gas permeable lenses OU and accidental right lens ejection

Ocular History: (limited due to language barrier)

- Keratoconus OU
- Penetrating keratoplasty OS (10+ years ago)

Medical History:

- Hypertension x 15 years controlled with medications

Presenting VAs: 20/400 @ 6 ft OD-sc, 20/40 OS-cc

- Minimal improvement in vision with manifest refraction OD, OS

Slit Lamp Exam Corneal Findings:

- OD: munson's sign, moderate inferior stromal thinning and scarring, mild band keratopathy inferior, moderate pannus inferior
- OS: mild to moderate neovascularization- greater inferior and trace edema surrounding corneal graft host junction 360 degrees, no residual surgical sutures

Initial Tried Diagnostic Lenses: Corneal and Intralimbal GPs

- Immediate failure due to poor lens fit and discomfort, OU

Diagnostic Scleral Lenses:

- OD: 6.04 BC / 16.5 OAD / 5400 SAG / -14.00 SPH / +6 SLZ Toric
 - Sphero-cylindrical over-refraction (ORx): +0.50-1.25x180 (20/40)
 - Fit Description: good centration and limbal coverage, 300um apical clearance and 100um limbal clearance, (-) blanching
- OS: 7.34 BC / 16.5 OAD / 5200 SAG / -12.00 SPH / +6 SLZ Toric
 - ORx: +6.75 (20/20)
 - Fit Description: good centration and limbal coverage, 400um AC and 50um LC, (-) blanching

Assessment:

- Severe Keratoconus OD and post-PKP OS
- Poor fit and comfort in corneal GPs and intralimbal GPs
- Good comfort, fit and vision with ORx with scleral lens OD and OS

Plan:

- Ordered:
 - OD: 6.04 BC / 16.5 DIA / 5400 SAG / -14.50 SPH / +6 SLZ Toric
 - OS: 7.34 BC / 16.5 DIA / 5200 SAG / -4.75 SPH / +6 SLZ Toric
- Monitor OS carefully for possible corneal edema with lens wear
- RTC 2 weeks for scleral lens dispense, I&R training and DFE or RTC sooner if problems arise

Corneal Tomography:

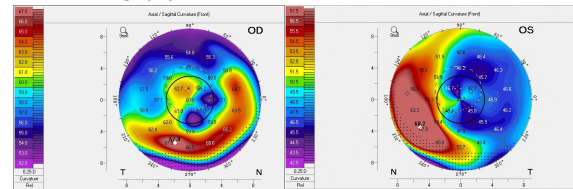


Figure 1. Initial corneal tomography scans via Pentacam indicating severe keratoconus, OD and severe irregular astigmatism PKP, OS.

Following Visits:

Visits:	Trial Lenses (Lens Material: Optimum Extra, Dk: 100 Fatt)	VAs & ORx	Subjective Report & Fit Evaluation
TRIAL 1	OD: 6.04 BC / 16.5 DIA / 5400 SAG / -14.50 SPH / +6 SLZ Toric (150um toric landing zone)	20/70 OD, 20/20- OS -1.25-0.50x155 (20/50)	Decent vision & comfort 100um AC and 50um LC, mild blanching
VISIT 2	OS: 7.34 BC / 16.5 DIA / 5200 SAG / -4.75 SPH / +6 SLZ Toric (150um toric landing zone)	-0.75-1.00x135 (20/20-)	450um AC and 300um LC, no blanching
TRIAL 2	OD: 6.04 BC / 16.5 DIA / 5400 SAG / -16.50-0.75x155 / +4 PCZ / +7 SLZ Toric (175um toric landing zone)	20/40- OD, 20/20- OS -0.50 D5 (20/40)	Much better vision & comfort 250um AC and 75um LC, no blanching
VISIT 3	OS: 7.34 BC / 16.5 DIA / 5000 SAG / -5.00-1.00x135 / +8 SLZ Toric (200um toric landing zone)	OS: plano (20/20-)	150um AC and 50um LC, no blanching
TRIAL 3	OD: 6.04 BC / 16.5 DIA / 5400 SAG / -16.50-0.75x155 / +4 PCZ / -3 SLZ / +10 SLZ Toric (250um toric landing zone)	20/40- OD, 20/20- OS OD: No improvement	Very good vision & comfort OD: 350um AC and 50um LC, no blanching
VISIT 4	OS: 7.34 BC / 16.5 DIA / 5000 SAG / -5.00-1.00x135 / +2 PCZ / +2 LLZ / -2 SLZ / +8 SLZ Toric (200um toric landing zone)	OS: No improvement	OS: 150um AC and 100um LC, no blanching

Table 1. Description of each lens trialed including VAs, ORx and fit description.

Abbreviation	Name	More Information	Abbreviation	Name
LLZ	Limbal Lift Zone	Standard: 0, adjustable in 1.0 steps (+/- 25um), from -15 to +15	BC	Base Curve
PCZ	Peripheral Cornea Zone		OAD	Overall Diameter
SLZ	Scleral Landing Zone		AC	Apical Clearance
SLZ Toric	Scleral Landing Zone-Toric Haptic	Standard: +6 (150um toric haptic), adjustable in 1.0 steps (+/- 25um)	LC	Limbal Clearance

Table 2. Abbreviations and general information for the scleral lens design parameters and fit description.

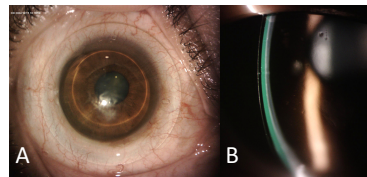


Figure 2. A) Gross picture of the trialed scleral lens on the right eye (severe keratoconus). B) Optic section of the scleral lens apical clearance (300 um) post-setting, right eye.

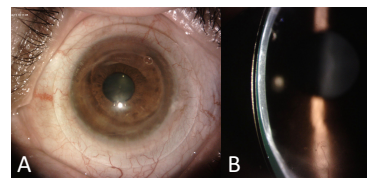


Figure 3. A) Gross picture of the trialed scleral lens on the left eye (post-PKP). B) Optic section of the scleral lens apical clearance (150 um) post-setting, left eye.

VISIT 5:

Patient presents with lenses on for at least 4-6 hours and reports good comfort with all day lens wear

Presenting VAs (cc): 20/30 no improvement with pinhole OD, 20/20- OS

Presenting & Final Lenses:

- OD: 6.04 BC / 16.5 DIA / 5400 SAG / -16.50-0.75x155 / +4 PCZ / -3 SLZ / +10 SLZ Toric
 - +4 PCZ: increased sagittal depth of lens 100um more than standard
 - 3 SLZ: flattened landing zone 75um more than standard
 - +10 SLZ toric: 250um back surface toric landing zone
 - ORx: plano
 - Fit: good centration, 200um AC and 50um LC, no blanching
- OS: 7.34 BC / 16.5 DIA / 5000 SAG / -5.00-1.00x135 / +2 PCZ / +2 LLZ / -2 SLZ / +8 SLZ Toric
 - +2 PCZ: increased sagittal depth of lens 50um more than standard
 - +2 LLZ: increased sagittal depth of lens over limbus 50 um more than standard
 - 2 SLZ: flattened landing zone 50um more than standard
 - +8 SLZ toric: 200um back surface toric landing zone
 - ORx: plano
 - Fit: good centration and limbal coverage, 150um AC and 50um LC, no blanching

Assessment and Plan:

- IOP (13 OD/15 OS) and DFE within normal limits
- Finalized scleral lenses
- Corneal Transplant not indicated at this time OD, continue to monitor
- RTC 6 months for dr-ordered f/u to monitor graft and neovascularization, OS or sooner if problems arise

Conclusions

Toric diagnostic SL fitting sets may expedite the fitting process for irregular corneas when scleral mapping technology is not available. When corneal GP lenses fail, SLs may provide improved vision and comfort. Consider utilizing reduced apical clearance and minimal lens center thickness to prevent corneal edema^{2,4}; the additional benefits of hyper-Dk lens materials has been questioned.^{1,2} As seen with this patient, one diagnostic fitting set was successfully utilized on two completely different ocular profiles in our patient. Versatile SL designs simplify the fitting process and allows practitioners the ability to handle a myriad of obstacles that may arise during the fitting period.

References

- Kumar, M., Shetty, R., Khamar, P., & Vincent, S. J. (2020). Scleral lens-induced corneal edema after penetrating keratoplasty. *Optometry and Vision Science*, 97(9), 697-702.
- Dhallu, S., Huarte, S., Bilkhu, P., Boychev, N., & Wolffsohn, J. (2020). Effect of Scleral Lens Oxygen Permeability on Corneal Physiology. *Optometry and Vision Science*, 97(9), 669-675.
- Vincent, S. J., & Bergmanson, J. P. G. (2022). Current Controversies in Scleral Lens Prescribing. *clsppectrum.com*. Retrieved November 7, 2022.
- Kumar, M., Shetty, R., Lalgudi, V. G., & Vincent, S. J. (2020). Scleral lens wear following penetrating keratoplasty: Changes in corneal curvature and optics. *Ophthalmic and Physiological Optics*, 40(4), 502-509.

Acknowledgements

We would like to thank Art Optical Contact Lens, Inc. for their continued support in furthering students' education and clinical experiences.