NECO | New England College of Optometry

Your Weapon of Choice in Early Keratoconus and Mild Corneal Scars: Soft Toric Lenses

Sydney M. Krisa, OD[1,2], Isabel H. Deakins, OD[1], Amy Watts, OD, FAAO[1,2]
[1] Massachusetts Eye and Ear Infirmary, [2] New England College of Optometry, Boston, MA

Mass General Brigham
Mass Eye and Ear

INTRODUCTION

Corneal irregularity, whether it's present from a degenerative disease or an innocuous condition, is visually disruptive. The lack of a smooth interface reduces visual quality and the success of correcting refractive error with spectacles alone. Specialty lenses provide a tailored solution for such irregularity by masking the surface asymmetry to provide improved optics.

While the capabilities of scleral lenses, RGPs, custom soft lenses, etc., are extensive, the fitting process can often be lengthy, expensive and daunting for many optometrists. Even though most moderate and advanced cases of corneal irregularity require this next step of contact lens expertise, mild cases have the potential to be corrected with standard commercially available soft toric lenses. This case series explores three patients with mild corneal irregularity and their results with non-customizable soft toric contact lenses.

MEET THE PATIENTS

	Demographic	Reason for visit
	66 year old Female	**PATIENT A** Discomfort and fluctuating vision in RGPs in setting of a corneal scar in the left eye.
	42 year old Female	**PATIENT B** Contact lens fitting in the setting of a corneal scar in the left eye with complaints of haze and blur in glasses.
	50 year old Male	**PATIENT C** Forme Fruste Keratoconus in both eyes and fluctuating vision in glasses diagnosed 1 year prior.

EXAM FINDINGS

PATIENT A **Corneal Scar OS**

- Chief Complaint: Patient was experiencing irritation and excessive movement with her RGP in the left eye and felt that her vision was adequate, but unstable.
  - Patient had discontinued RGP wear 1 week prior due to these issues.
- Medical History: Ulcerative Colitis.
- Ocular History: Anterior stromal scar from unknown cause in the left eye, pseudophakia of both eyes.
- Slit lamp exam: Unremarkable except for a faint round anterior stromal scar at 10:00 in the left eye.
- Posterior segment exam: Unremarkable in the right eye, trace macular mottling in the left eye.

PATIENT B **Corneal Scar OS**

- Chief Complaint: Patient was interested in contact lenses due to issues with haze and blur in the left eye in her spectacles.
- Medical history: Unremarkable.
- Ocular history: History of P. acnes corneal ulcer of left eye.
- Slit lamp exam: Unremarkable except for a small central scar in the left eye.
- Posterior segment exam: Unremarkable OU.

PATIENT C **Forme Fruste Keratoconus OU**

- Chief Complaint: Referred for RGP or custom soft lens fitting in setting of early keratoconus.
- Medical History: Unremarkable.
- Ocular History: Forme Fruste keratoconus
- Slit lamp exam: Unremarkable OU.
- Posterior segment exam: Unremarkable OU.

Patient	Manifest Refraction	Vision
A	-0.50 -1.75 x 030 OS	20/40-2
B	-5.50 -0.75 x 095 OS	20/20-1
C	-5.50 -2.00 x 085 OD -7.50 -1.50 x090 OS	20/40 +2 20/20 +1

IMAGING

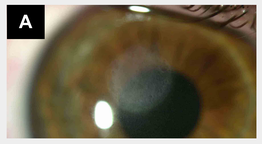

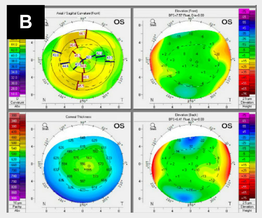

PATIENT A

***Slit Lamp Photos: (A)** Photo of the left eye with the focus on the cornea. A faint central circular corneal opacity is visible bisecting the visual axis.[4]

***NOTE:** Image A is not of the patient, but rather depicts a representation of the patient's corneal opacity.[4]

Corneal Topography: (B) Displays patchy irregular areas of corneal curvature, with higher dioptric values noted at 120 degrees in the location of the corneal scar. Noteworthy numbers are 0.9D of corneal astigmatism and a K max of 47.1 D.

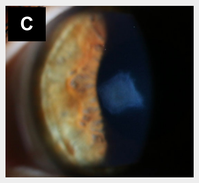

PATIENT B

Slit Lamp Photos: (A, C) Photos of the left eye. A faint gray central corneal opacity is visible within the pupil.

Corneal Topography: (B) Displays irregular corneal curvature with areas of central flattening second to a corneal ulcer. Noteworthy numbers are 1.8D of corneal astigmatism and a K max of 46.7 D.

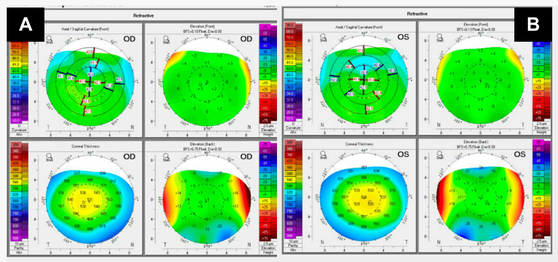

PATIENT C

Corneal Topography: (A,B) Displays mild posterior surface elevation of both eyes with associated areas of corneal thinning.

CONTACT LENS FITTING RESULTS

	Previous CL	New Fit CL	Follow-up
PATIENT A 66 yr old F **Corneal Scar**	**Lens**: Boston ES Blue / 7.90 / 9.1 / plasma / 0.5 std steep edge OS: PL -1.50 x 025	**Lens:** Comfilcon A/ 8.7/ 14.5/ OS: -0.50 -1.25 x 30	**1.5 month f/u:** **Lens**: Comfilcon A/ Multifocal / 8.7 BC/ 14.5 DIA/ -0.50 -1.25 x030 ADD +2.00D
	VA with ORx: **20/25-3 OS**	**VA with ORx**: **20/25+1 OS**	**VA with ORx:** **20/20-2 OS**
	Fit: Sits slightly inferior with alignment pattern and adequate edge lift 360	**Fit:** Good coverage, centered, no rotation, subjective improvement in comfort	**Fit**: Centered, good coverage, 0.5mm movement, no rotation
PATIENT B 42 yr old F **Corneal Scar**	**Trial Lens:** Boston EO 8.0/ 9.6/ OS -3.00 DS	**Lens:** Comfilcon A/ 8.7BC/ 14.5 DIA/ OS: -4.00 -0.75 x090	**1 month f/u**: VA: **20/30 OS**, but lens had accumulated significant debris. **3 month f/u:** VA: **20/20 OS** with over refraction
	VA with ORx: **20/25+ OS**	**VA with ORx**: **20/20- OS**	
	Fit: Mild central touch, mid-peripheral pooling, excessive edge lift, slightly decentered	**Fit**: Well centered with adequate coverage, no rotation, good movement	
PATIENT C 50 yr old M **Forme Fruste KCN**	**Lens**: Spherical Comfilcon A (unknown power)	**Lens**: Comfilcon A/ 8.7 BC / 14.5 DIA OD: -5.25 -1.75 x090 OS: -5.50 -1.25 x090	**1.5 month f/u:** **Lens**: Comfilcon A/ 8.7 BC/ 14.5 DIA OD: -4.50 -1.75 x090 OS: -5.50 -1.25 x090
	VA: **20/40+ OD, 20/25+ OS**	**VA with ORx**: **20/20- OD, 20/20 OS**	**VA with ORx:** **20/20 OD, 20/20 OS**
	Fit: Decentered OU	**Fit:** Centered, good coverage, no rotation, good movement	**Fit**: Centered, good coverage, 0.5mm movement, no rotation

SELECTING THE BEST LENS

To minimize chair time and maximize efficiency, the first important decision when performing a contact lens fit in the setting of irregular corneas is deciding whether a speciality lens is indicated. If a patient has mild corneal astigmatism, mild to moderate K's and a healthy tear lake, a soft toric could be a good place to start. Other factors to consider in regards to specialty lenses include:

- **Lens handling**: Hand steadiness, ability for full control of fine motor skills, and neck mobility for scleral lenses.
- **Mobility issues:** Patients suffering from tremors, neck pain, or mobility issues often have trouble inserting scleral lenses.[6]
- **Comfort and wear time**: RGP lenses are often uncomfortable for new wearers and require consistent wear time to adapt to lenses.
- **Cost and convenience**: Soft toric lenses are reasonably priced, readily available, and can be purchased anywhere.
- **Occupation and hobbies**: Patients in dusty environments might do better in a soft toric lens rather than a corneal GP.

If choosing a soft toric lens, the next step is to decide which lens:

Important Characteristics in Choosing a Soft Toric lens:		
Characteristic	Definition	Note
Modulus of Elasticity	The measurement of the material's resistance to deformation under tension.[5]	The more rigid the soft lens, the higher the modulus.
Lens Stability	Techniques to secure that the correcting cylinder is at the appropriate axis for precise alignment with the eye.[3]	Greater irregular corneal astigmatism will cause greater rotational instability.

With commercially available soft toric lenses, customization is available only when comparing brands, so the optimal lens can be chosen for the patient by evaluating the variable parameters between each lens design. For irregular corneas, a higher modulus of elasticity creates a more rigid surface that can can help to mask the corneal asymmetry. The lenses selected in this case series had a modulus of 0.75 MPa, which falls in the middle to high range among lenses.[2]

For stabilization, there are various options available including:

- Truncation
- Prism ballast
- Peri ballast
- Back-surface toricity and more.

The lenses in this case series utilized a proprietary stabilization method that is a variation of the prism-ballasted design, with base-down prism to make the lower portion of the lens thicker to facilitate proper lens orientation.[1]

CONCLUSION

- Avoid fitting bias and don't assume a patient will do the best in a specialty lens just because their chart says "irregular cornea."
- Explore higher modulus lenses for mild corneal irregularity in order to mask the asymmetric surface.
- With limited customization available in an individual commercial soft toric lens, evaluate the parameters that vary between brands to select the best lens for the patient.
- Rotational stability is most important for consistent optics, different soft lens stabilization techniques might be effective for different patients.
- Overall, it's okay to keep it simple. Sometimes the easiest solution is the best one!

REFERENCES

1. Barnett, M. (2018). Toric Lens Designs. *Contact Lens Spectrum.*
2. (2022). Biofinity Toric Parameters and Specs. *Optix: Your Vision Care Guide*.
3. Edrington, T. (2011). A literature review: The impact of rotational stabilization methods on toric soft contact lens performance. *Contact Lens & Anterior Eye*, 34 (2011) 104-110.
4. Gasson, A. (2022). A London Contact Lens Specialist Photo Gallery. Speak Digital.
5. Ghormley, R. (2005). How Modulus Affects Soft Contact Lenses. *Contact Lens Spectrum.*
6. Patel, P (2021). Backtracking From Scleral Lenses: When Custom Soft Lenses Get the Job Done. *Global Insight*.