Complications of Scleral Lens Fitting for Treatment of Limbal Stem Cell Deficiency

Alyssa Calta, OD, Sarah Bell, OD, Sudeep Pramanik, MD, MBA, FACS

SALUS UNIVERSITY

Mid-Atlantic Cornea Consultants

BACKGROUND

Using large diameter scleral lenses in patients with ocular surface disease like limbal stem cell deficiency (LSCD) continue to gain popularity when other treatments are insufficient.[1] LSCD occurs with damage to limbal stem cells and may lead to corneal opacification and blindness.[1] Scleral lenses can improve vision and provide a protective environment for the ocular surface, but care must be taken to properly fit these patients to avoid complications that may worsen LSCD.[1]

CASE DESCRIPTION

- An established 65-year-old female here for a new scleral lens fitting
- **Ocular history:** myopic degeneration, perifoveal neovascularization, and limbal stem cell deficiency (Fig. 1) following LASIK and an enhancement 1 year later.
- **LSCD/DES treatment history:** tears, punctal plugs, IPL, multiple AMGs, Restasis, methylprednisolone, and more.
- One week after taking her new, 19mm diameter scleral lenses home, she returned urgently complaining of…
    - burning and pain in her right eye after about an hour of scleral lens wear and difficulty inserting and removing the lenses. Discussed continuing to practice and see back in 1 month.

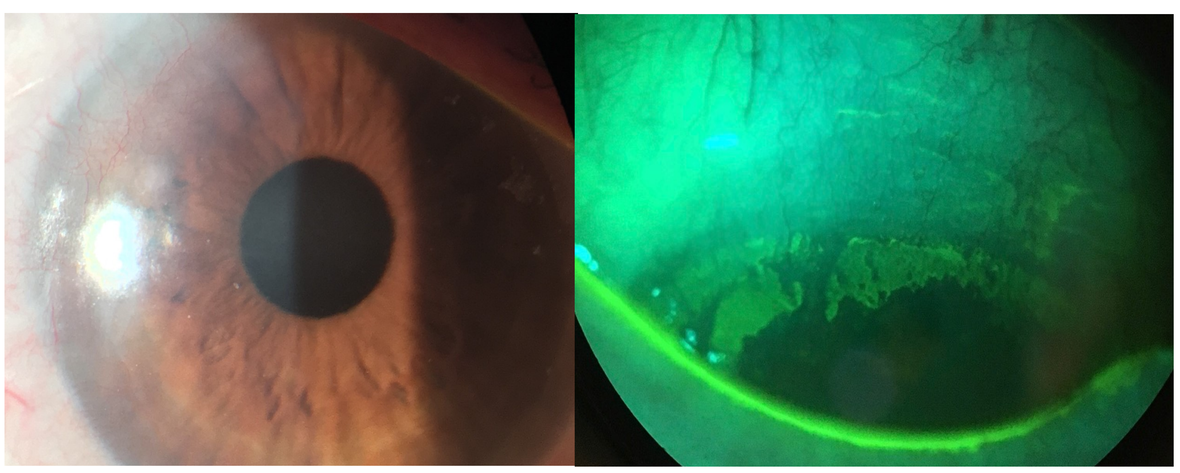

Figure 1. Neovascularization and corneal staining due to LSCD



Figure 2. Lens edge before and after channels were added

LENS ADJUSTMENTS

- **One month later:** the patient returns complaining of significant suction when removing the lenses. Excellent insertion and removal technique in office.
- **Changes made to new lenses:** channels added nasally and temporally to reduce suction.
- **One month later**: the new lenses with the channels were placed on the eyes with a great fit, including limbal clearance (Fig. 2 and 3), and excellent monovision. The patient also noted easier removal.



Figure 3. Ideal limbal clearance

CONCLUSIONS

Despite myopic degeneration and a history of neovascular membranes, the patient achieved 20/20 vision at distance and near using monovision scleral lenses. The lenses not only improve her best correct acuity from 20/30 to 20/20 in each eye, but it serves as a therapeutic shell to protect her stem cells and promote healing. She is scheduled for a follow-up to check in the improvement in her LSCD signs and symptoms.

Large diameter scleral lenses should be considered to improve vision and comfort in LSCD. Consider adding channels during the initial fit for these patients to reduce suction. Suction can lead to limbal edema and eventually increased peripheral neovascularization, so careful attention to this aspect of the fit must be given in LSCD patients.[2]

REFERENCES

1. Bonnet, C., Lee, A., Shibayama, V. P., Tseng, C.-H., & Deng, S. X. (2021). Clinical outcomes and complications of fluid-filled scleral lens devices for the management of Limbal Stem Cell deficiency. *Contact Lens and Anterior Eye*, *46*(1), 101528.
2. [BostonSight]. (2020, September 1). *SCLERAL | Crash Course in the Use of SmartChannel Technology* [Video].