



# Correcting Crumby Vision: The Use of Scleral Lenses for Management of Granular Dystrophy

Riley Parker, BA; Josh Lotoczky, OD, FAAO; Emily Gottschalk, OD, FAAO; Chad Rosen, OD, MBA, FAAO

## Background

Granular corneal dystrophy type I (GCDI) is an autosomal dominant stromal dystrophy resulting from mutations in the TGFB1 gene.<sup>1</sup> It is characterized by well demarcated breadcrumb-shaped opacities in the central anterior stroma. The dystrophy appears in adolescence or early adulthood and is accompanied by late diffuse corneal haze, reduced visual acuity, glare, and photophobia. As the condition progresses the hyaline deposits coalesce and run deeper into the stromal layer which causes decreased corneal sensitivity.<sup>1</sup> The deposits may cause corneal epithelial erosions, for which initial treatment includes the use of artificial tears and bandage contact lenses. Surgical methods used for the treatment of granular corneal dystrophy include phototherapeutic keratectomy (PTK) and deep anterior lamellar keratoplasty (DALK).<sup>2</sup> This case aims to discuss the use of scleral contact lenses to manage granular corneal dystrophy type 1.

Scleral contact lenses are designed to vault over the entire corneal surface, resting on the sclera. These lenses offer correction of visual symptoms caused by a variety of ocular surface diseases and corneal ectasias. A fluid reservoir forms between the lens and the cornea, smoothing surface irregularities, providing relief for those with ocular surface disease and allowing for healing of the ocular surface. Primary indications for use of scleral lenses includes ocular surface disease, corneal irregularity, and severe refractive error.<sup>3</sup>

## Case Details and Management

A 26-year-old white male presented with chief complaints of glare and haze, intermittent dryness, monocular diplopia, and a history of GCDI. The patient reported working as a technician at an ophthalmology practice. Prior to arrival, he had been educated on the need for PTK or high-order aberration correcting lenses from a corneal specialist. The patient was adamant about avoiding surgery yet had extremely specific standards for his visual performance. Treatment using wavefront guided scleral contact lenses was unsuccessful due to patient discomfort and dissatisfaction with glare reduction. The patient presented with entering unaided acuities of 20/30- OD, 20/40 OS and 20/25- OD and OS through his habitual scleral lenses. Slit-lamp examination revealed severe opacities located in the central anterior stroma. The breadcrumb-shaped opacities spanned the central 5-6mm of the cornea, interfering with the visual axis. Additionally, signs of dry eye disease and tear film irregularities were observed. The patient also displayed pingueculas temporally OU and nasally OD. The patient was fit in a 15.80 mm quadrant-specific scleral lens which allowed for edge vaulting over the three pingueculas and provided patient comfort to treat symptoms of glare, haze, and dry eye disease. A larger optic zone diameter, 9.0 mm, was used to alleviate symptoms of glare and monocular diplopia. The patient was educated that disease progression had occurred and would likely continue. Additional education included the possibility of PTK or DALK in the future, but he was reassured that best vision and comfort would be found using scleral contact lenses.

Refractive Data			
	Subjective Refraction	Visual Acuity	Manual Keratometry
OD	+0.25 -1.25 x 115	20/20-2	42.75 x 020 43.62 x 110
OS	+0.75 -2.00 x 079	20/25-2	43.37 x 157 44.50 x 067
Finalized Lens Parameters			
	OD	OS	
BC	8.23 mm	8.23 mm	
Diameter	15.80 mm	15.80 mm	
Optic Zone Diameter	9.0 mm	9.0 mm	
Edge Vault Height	0.30 µm	0.30 µm	
Edge Vault Width	30.0 µm	30 µm	
Edge Vault Angle	45.0	130	
Sagittal Depth	4.573 µm	4.520 µm	
Power	+4.00 -1.25 x 120	+4.00 -1.00 x 050	
Visual Acuity	20/20-	20/20-	




Figure 1. Image showing distorted mires on topographical software due to corneal and tear film irregularities. Data was unable to be obtained due to severity.

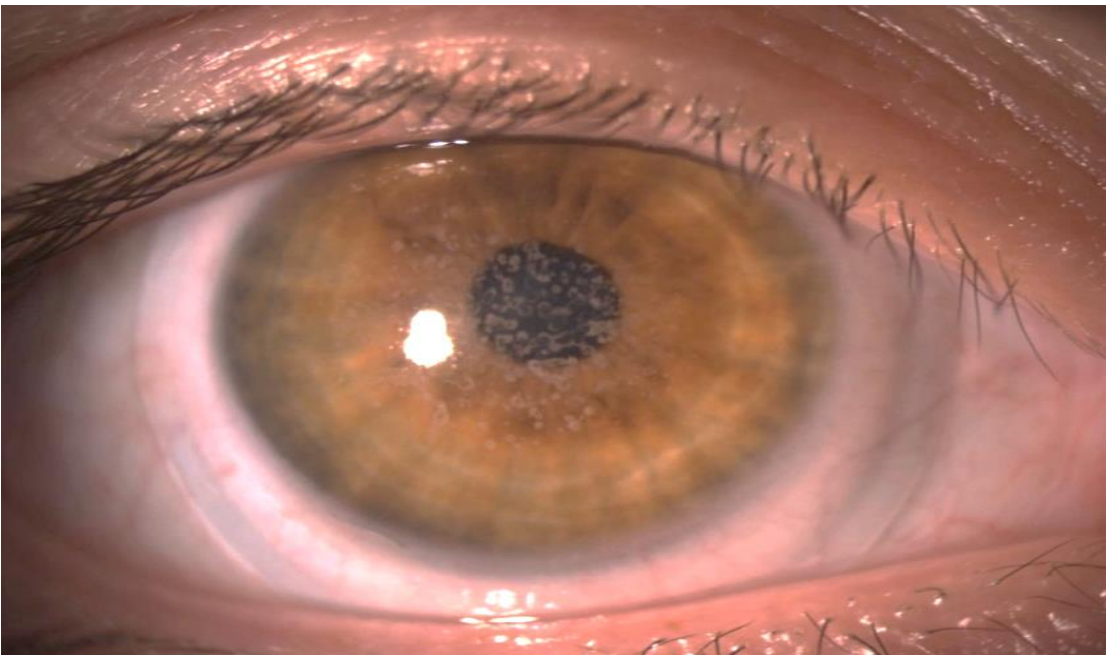


Figure 2. Image of finalized scleral lens on the right eye.

## Discussion

Scleral contact lenses allowed this patient to overcome the symptoms of his disease and delay the need for surgery. Due to chromatic aberrations that occur from corneal opacities, patients with GCDI are often unable to function using spectacle correction. Tear film and corneal surface irregularities, and multiple pingueculas restricted this patient from being able to wear soft contact lenses. Once the opacities decrease visual acuity, PTK surgery may be performed. PTK surgery uses an excimer laser to remove opacities located in the anterior stroma.<sup>4</sup> DALK surgery may be considered with deep stromal deposits or when PTK is no longer repeatable.<sup>5</sup> Following either surgery, there is no statistical improvement in visual acuity for the patient with GCDI. Additionally, recurrence within the corneal graft material is almost universal within four years of surgery.<sup>6</sup> Therefore, delay of surgery is crucial to managing the young patient with corneal irregularities such as those found in GCDI, in addition to other dystrophies and ocular surface disease. The use of scleral lenses to delay corneal surgery is not limited to GCDI; rather, scleral lenses may delay corneal surgery for numerous corneal dystrophies, degenerations, ocular surface diseases, post-trauma, and even post-surgery.

## Conclusion

A diagnosis of GCDI typically leads to surgical referral for PTK or DALK procedures. However, scleral lenses with standard optics can correct for aberrations and other ocular sequelae resulting from corneal surface irregularities. Therefore, scleral lenses should be used to correct visual function and comfort of symptoms related to corneal surface disease. The lack of visual acuity improvement, risk of recurrence, and limitation of repeatability after PTK or DALK procedures should inspire delay of surgery. For the young patient, scleral lenses should be the management of choice to delay surgery and inevitable recurrence, in addition to reducing symptoms caused by corneal surface irregularities such as those seen in GCDI.

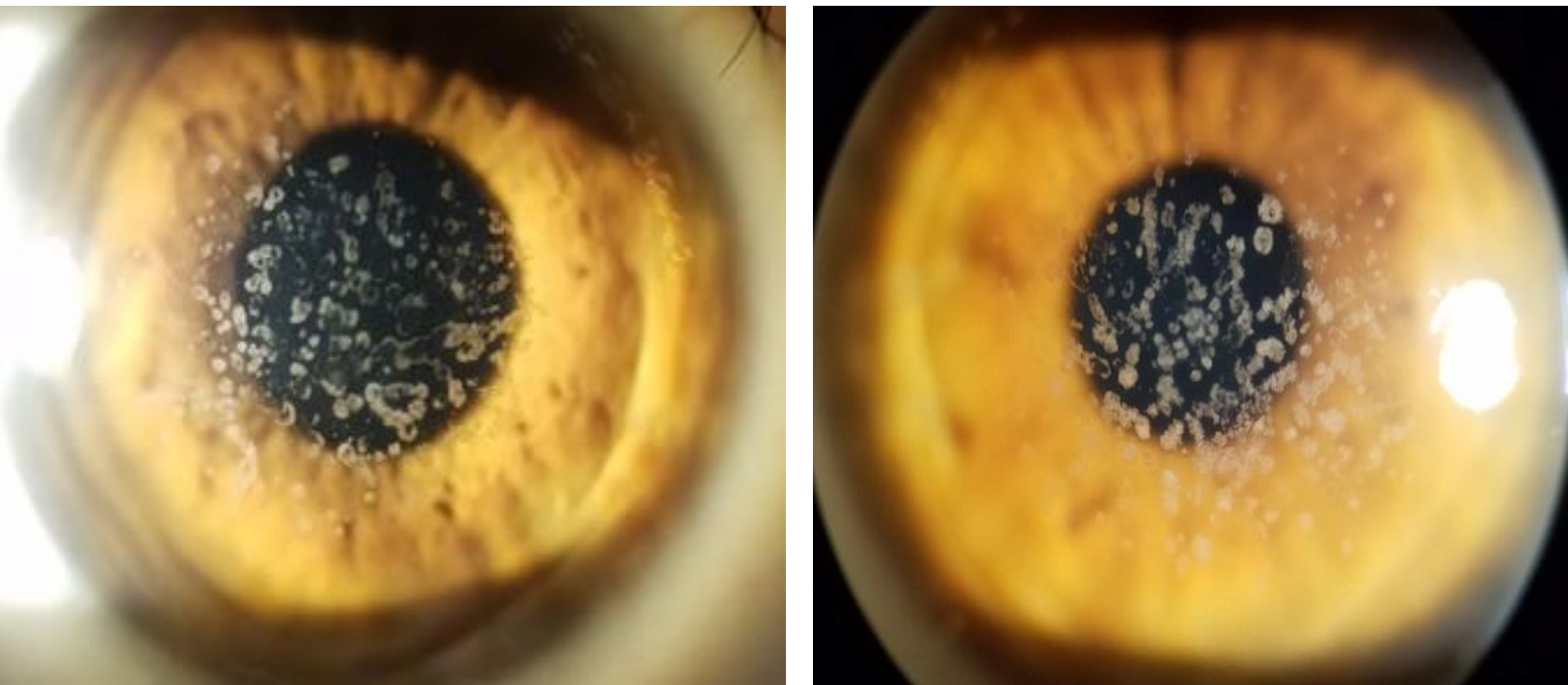


Figure 3. Photos of breadcrumb shaped opacities spanning the central anterior stroma of both eyes. Right eye image shows less severe opacification (left) compared to the left eye (right).

## References

- Jun, AS. "Granular Corneal Dystrophy." *Johns Hopkins Medicine*, Aug. 2021.
- Chang MS, Jun I, Kim EK, "Mini-Review: Clinical Features and Management of Granular Corneal Dystrophy Type 2." *Korean Journal of Ophthalmology : KJO*, U.S. National Library of Medicine, Aug. 2023.
- Weiner, G. *Update on scleral lenses*. American Academy of Ophthalmology. May 2020.
- Maclean H, Robinson LP, Wechsler AW, Goh A. Excimer phototherapeutic keratectomy for recurrent granular dystrophy. *Aust N Z J Ophthalmol*. 1996;24:127–30.
- Ellies P, Renard G, Valleix S. Clinical outcome of eight BIGH3-linked corneal dystrophies. *Ophthalmology*. 2002;109:793–7.
- Lyons CJ;McCartney AC;Kirkness CM;Ficker LA;Steele AD;Rice NS; "Granular Corneal Dystrophy. Visual Results and Pattern of Recurrence after Lamellar or Penetrating Keratoplasty." U.S. National Library of Medicine, Nov. 1994.