1

Disclosures

Norma Cardenas – Director of Professional Services at Menicon America Latina

Karen Carrasquillo – Salaried Employee of BostonSight. No Financial or proprietary interest in any BostonSight Products

Daddi Fadel– Is a speaker for the following companies: Augmented Vision Labs, Bausch + Lomb, Boston Materials, BostonSight, Chio by Clara, Contamac, DMV, Eaglet Eye, EasLac, Hakim Group, Medlac, Medmont, Menicon, Multilens, Occhio x Occhio, Oculus, Optiforum, Scleral Lens Society, Scope, SynerEyes, Swisslens, Topcon Healthcare, Wave Software

Patricia Flores– Salaried Employee of Menicon. No Financial or proprietary interest in any Menicon Products

2



AGENDA

- **Central** — Touch corneal, Corneal Edema, Bogging
- **Limbal** — Limbus touch
- **Landing** — Impingement / Blanching, Notches & Customization
- **Centration** — Conjunctival Prolapse, Lens decentration
- **Surface and vision** — Midday Fogging, Vision Problems

3



AGENDA

- **Central** — Touch corneal, Corneal Edema, Bogging
- **Limbal** — Limbus touch
- **Landing** — Blanching, Notches & Customization
- **Centration** — Prolapse conjuntiva, Lens decentration
- **Surface and vision** — Midday Fogging, Vision Problems

4

Corneal Touch

- Scleral designs are meant to vault the cornea and are not expected to provide any area where the lens and the cornea are in direct contact.

CLINICAL SIGNS

- Corneal touch or bearing (punctate, coalescent, or arcuate staining)
- If this happens, it means that the lens has insufficient clearance, and it can be central or peripheral.

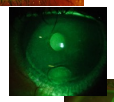

Daddi Fadel

Walker MK, Bergmanson JP, Miller WL, et al.: Complications and fitting challenges associated with scleral contact lenses: A review.Cont Lens Anterior Eye. 2016;39(2):88-96

5

Corneal Touch

ASSESMENT

Insufficient central clearance

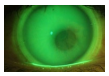

Central corneal touch

- The assessment of this complication can be done with the lens on the eye, and using fluorescein with a blue light and a yellow filter, or without the lens (after removal) to see if there is presence of any corneal staining.
  - If staining is central, and it matches with the corneal apex, sagittal height must be increased.
  - If staining is circular on periphery, the lens diameter must be increased.

Peripheral corneal touch

Staining peripheral touch

Walker MK, Bergmanson JP, Miller WL, et al.: Complications and fitting challenges associated with scleral contact lenses: A review.Cont Lens Anterior Eye. 2016;39(2):88-96

6

Corneal Touch

MANAGEMENT

Central corneal touch:

- Flat fitting: Increase the sagittal height for a clearance of 200-250 µm.

Peripheral corneal touch:

Small diameter: Increase the lens diameter

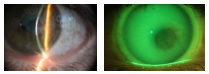

Insufficient central clearance

Central corneal touch

Peripheral corneal touch

Staining peripheral touch

Walker MK, Bergmanson JP, Miller WL, et al.: Complications and fitting challenges associated with scleral contact lenses: A review.Cont Lens Anterior Eye. 2016;39(2):88-96

7



AGENDA

- Central
  - Corneal Edema
- Limbal
  - Limbus touch
- Landing
  - Blanching
  - Notches & Customization
- Centration
  - Prolapse conjunctiva
  - Lens decentration
- Surface and vision
  - Midday Fogging
  - Vision Problems

8

Ocular Assessment - CORNEA

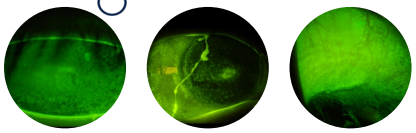

Staining Patterns Tell The Story

9

Ocular Assessment - CORNEA

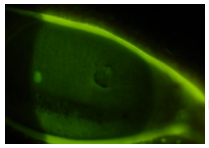

Critical –

Recurrent corneal abrasions

Determine root cause

10

Ocular Assessment - CORNEA

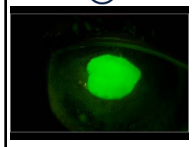

Critical –

daily stromal thickness assessment

11

Ocular Assessment - CORNEA

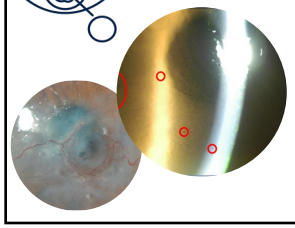

Corneal Edema

Etiologies:

- Present at Baseline?
- Disease
  - Root Causes

12

Ocular Assessment - CORNEA

Courtesy: Dr. Bita Asghari

Case (Lens Intolerance/Corneal Edema)

52 y/o Caucasian male
Bilateral PKP 2° KCN
No Baseline edema
Goal: improve BCVA

CC:
Difficulty with lens removal
Rebound redness
Tolerance reduced from 12hrs/day ⇒ 8hrs/day

WHAT's THE CAUSE?

AGAIN:
ALWAYS REMOVE
THE LENS AND STAIN!

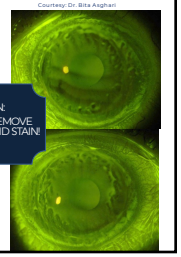

13

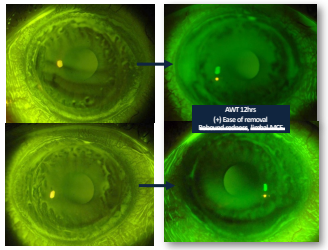

14

Ocular Assessment - CORNEA

Case (Corneal Edema)

65 y/o Caucasian female
H/O PMD OU OS>>OD
SUCCESUL LENS WEAR X 10 yrs
NO PREVIOUS Hx of EDEMA

WHAT's THE CAUSE?



15

Ocular Assessment - CORNEA

Case (Corneal Edema)

65 y/o Caucasian female
H/O PMD OU OS>>OD
SUCCESFUL LENS WEAR X 10 yrs
NO PREVIOUS Hx of EDEMA

WHAT's THE CAUSE?
WHAT WOULD YOU DO NEXT
TO PROPERLY Dx CAUSE?

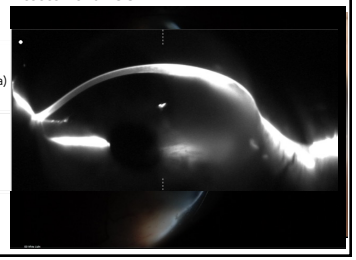

16

Options?

- Steroids
- D/C Lens
- Gas injection in the Anterior Chamber
  - SF_6
  - C_3F_8
- Corneal Transplant

17

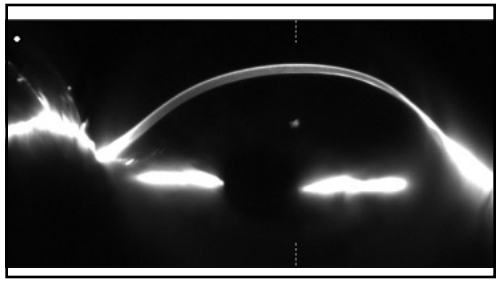

18

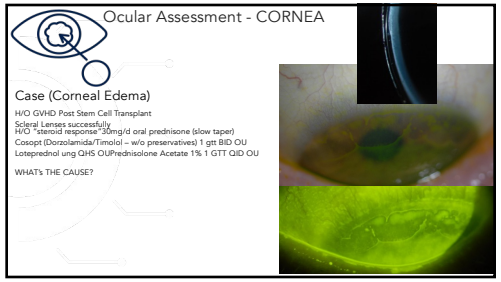

19

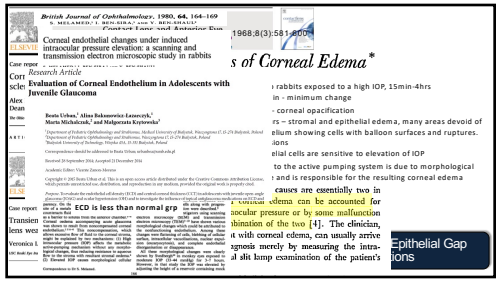

20

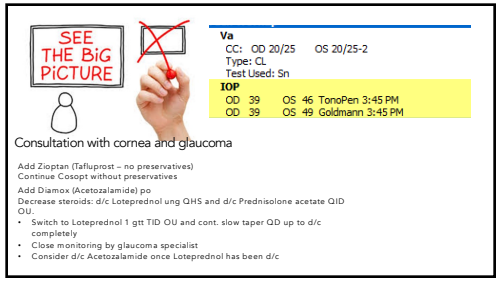

21

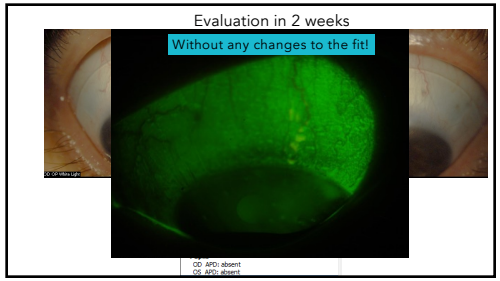

22

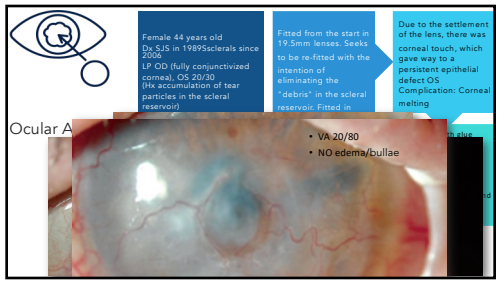

23

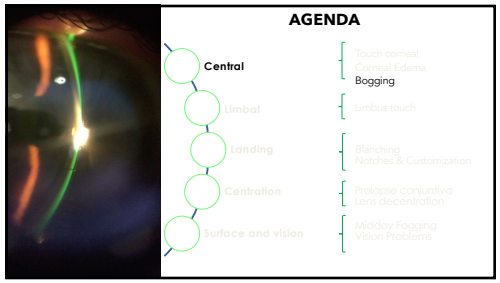

24

Bogging

Symptoms / Signs	Etiology	Management
• Asymptomatic • Superficial epithelium with corrugated, wavy fluorescein. • Transient condition.	Inmersion prolongada de la córnea en una solución con preservantes	• Use preservative-free solutions. • Mix: Preservative free lubricant + sodium chloride solution. • Replacement after 5 hours of use.

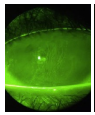
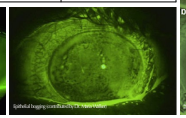
Epithelial bogging seen illustrated by fluorescein staining.
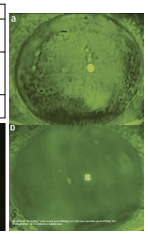
Bogging. Photo by Dr. Jack Lin, Bogging, Dry eye and Non-sterile pure filling. Dr. Photography of Tomorrow Conference.

25



AGENDA

- Central — Touch corneal, Corneal Edema, Bogging
- Limbal — Limbus touch
- Landing — Blanching, Notches & Customization
- Centration — Prolapse conjuntiva, Lens decentration
- Surface and vision — Midday Fogging, Vision Problems

26

Limbal Touch

ADVERSE IMPACT TOUCH LIMBAL AREA

- Limbal stem cells: Renewal and proliferation of the corneal epithelium and help ensure corneal health
- Breakdown of epithelium in the presence of harsh limbal touch
- Discomfort: In cases with heavy bearing in this region with a high density of sensory nerve endings

Walker MK, Bergmanson JP, Miller WL, et al.: Complications and fitting challenges associated with scleral contact lenses: A review.Cont Lens Anterior Eye. 2016;39(2):88-96

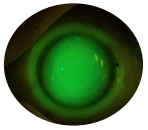
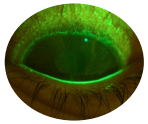

27

Limbal Touch

CLINICAL SIGNS

- Limbal staining
- Insufficient clearance over the limbus
- Dark area over the limbus

Optimal Limbal Clearance

- Depends on Total Diameter
- Diametre = 16,50 mm:
  - = 60 - 80 µm
- Diametre ≥ 16,50 mm:
  - = 80 - 100 µm

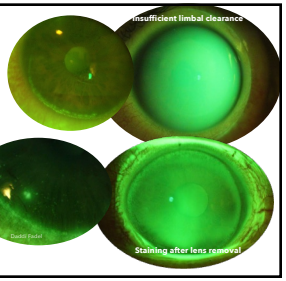

28

Limbal Touch

CAUSES

- Toric or asymmetrical ocular surface
- Periphery of posterior surface Toric
- Specific quadrant design
- Custom haptics
- Design by Molding/Printing

Management

- Dynamic evaluation, toric haptics
- Increase diameter
- Switch to a lens with an oval optical zone

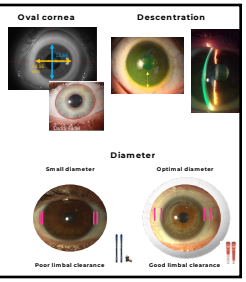

29

Limbal Touch

ASSESMENT LIMBAL CLEARANCE

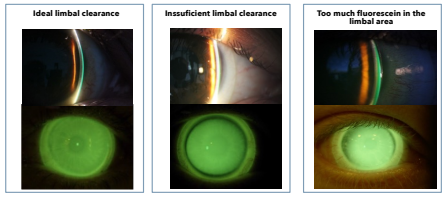

30

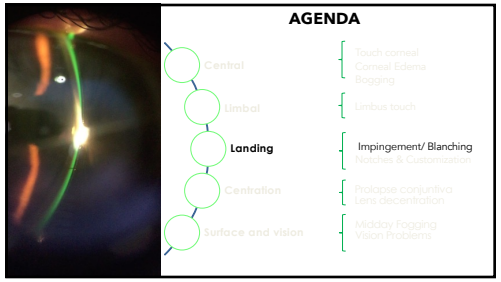

31

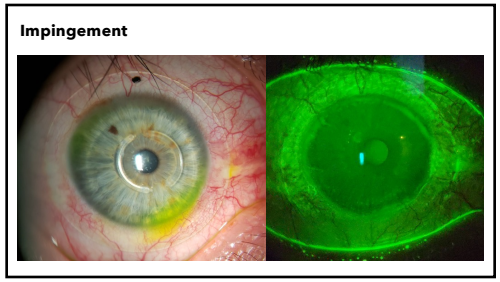

32

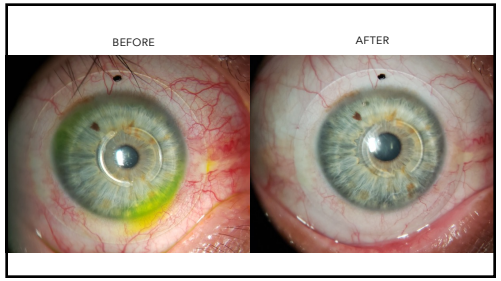

33

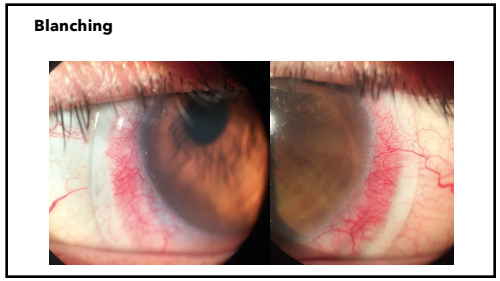

34

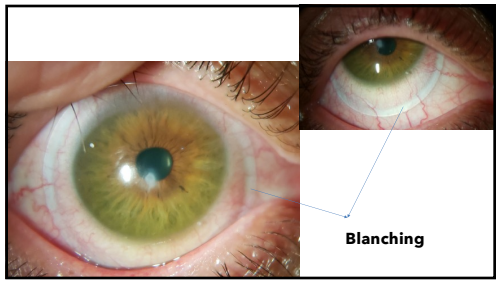

35

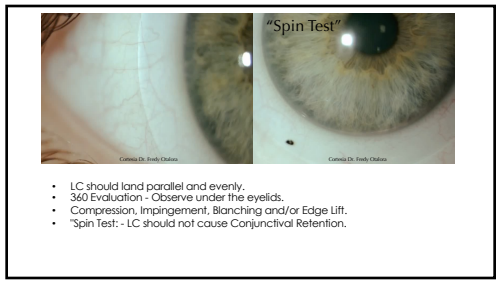

36

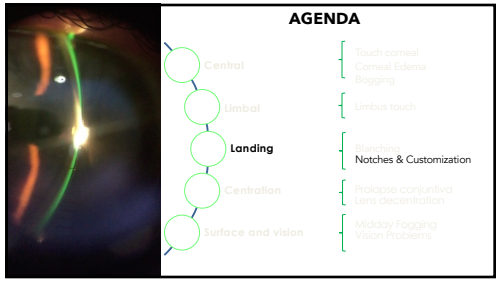

37

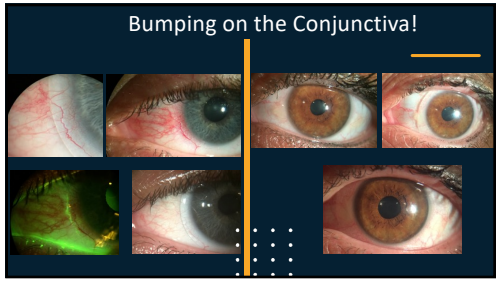

38

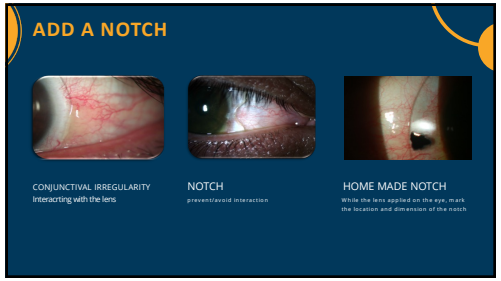

39



40



41

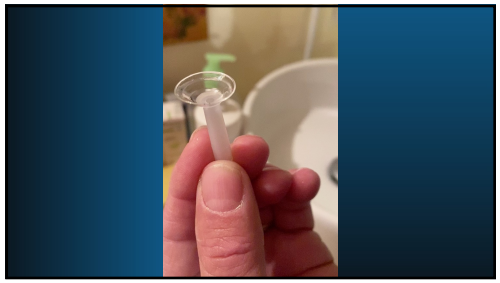

42

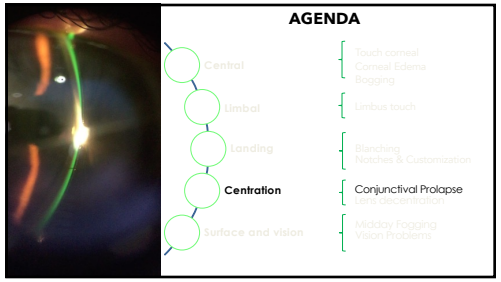

AGENDA

- Central — Touch corneal, Corneal Edema, Bogging
- Limbal — Limbus touch
- Landing — Blanching, Notches & Customization
- **Centration** — Conjunctival Prolapse, Lens decentration
- Surface and vision — Midday Fogging, Vision Problems

43

Conjunctival Prolapse

Etiology	Symptoms/Signs
• Mature age • Conjunctivochalasis • Lax Conjunctiva • Lower decentered LC • Excessive limbal clearance • Associated with PMD	• Conjunctival tissue in limbus and/or Cornea • Neovascularization

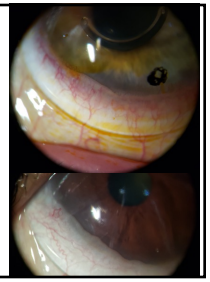

44

Conjunctival Prolapse

Solution
• Reduce the limbal space. • Perform Toric Haptics. • Decrease LC Total Diameter • Monitor for neovascularization / Ophthalmology.

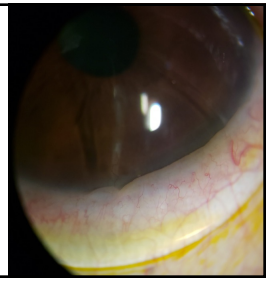

45



AGENDA

- Central — Touch corneal, Corneal Edema, Bogging
- Limbal — Limbus touch
- Landing — Blanching, Notches & Customization
- **Centration** — Prolapse conjuntiva, Lens decentration
- Surface and vision — Midday Fogging, Vision Problems

46

LENS DECENTRATION

SYMPTOMS

- Discomfort
- Reduced visual acuity
- Induced aberrations with reduced visual quality

CLINICAL SIGNS

- Scleral lens off-center
- Different clearance thickness in the peripheral cornea and limbal zone, in the different quadrants
- Thinner tear fluid reservoir or dark area, generally in the superior-nasal quadrant
- Corneal edema

OBSERVATION

Slit lamp – Eye in the straight gaze directions.

- Diffuse illumination + White light
- Diffuse illumination + Blue light + NaFl
- α: 5-12A
- Optic section 10-14x

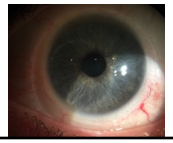

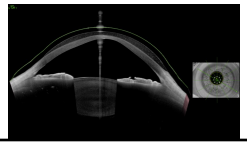

47

LENS DECENTRATION

- Induce midday fogging
- Induce a prismatic effect
- Lens movement and instability
- Reduce VA & comfort

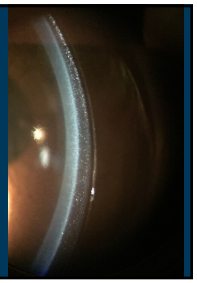

48

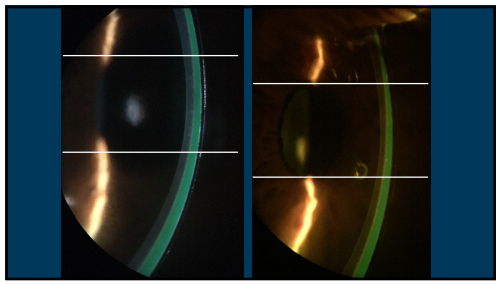

49

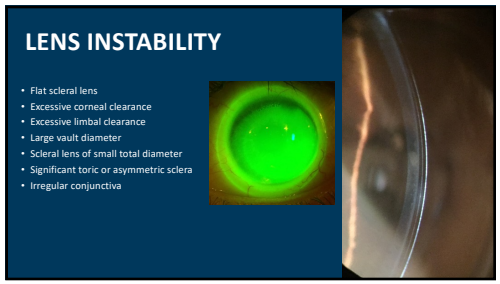

50

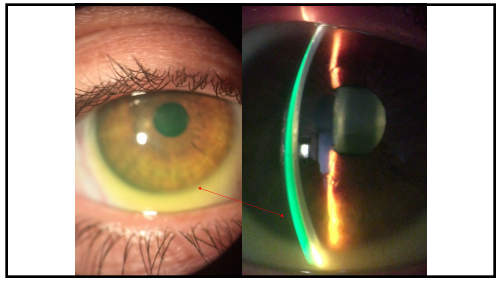

51

52

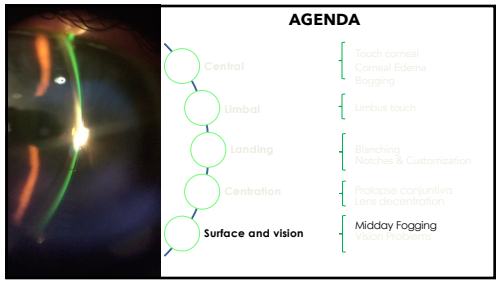

53



54

MIDDAY FOGGING

A positive correlation was found between debris and VA

- Turbid reservoir leads to a decrease in VA of at least two lines in 45% eyes (Rathi et al., 2012)
- Turbidity reduced high contrast VA and contrast sensitivity after 6–9 hours of scleral lens wear (Carracedo et al., 2017)
- Turbidity casued also reduction of about 1 line in keratoconus patients without ICRS and reduction of 2–3 letters in patients with ICRS (Carracedo et al., 2017)

- Rathi VM, Mandathara PS, Vaddavalli PK, Sikarath, Sangwan VS. Fluid filled scleral contact lens in pediatric patients: challenges and outcomes. Cont Lens Anterior Eye. 2012;35:271–274.
- Carracedo G, Serramito-Garcia R, Martin-Gil A, Wang Z, Rodriguez-Porter C, Pintor J. Post-lens tear turbidity and visual quality after scleral lens wear. Clin Exp Optom. 2017;100:577–582.

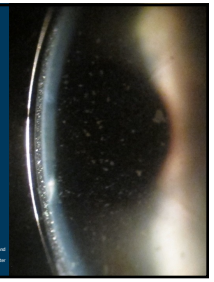

55

MIDDAY FOGGING

MULTIFACTORIAL

ETIOLOGY
- Adaptation of the ocular surface
- Blepharitis
- Allergy
- Excessive central clearance
- Excessive limbal clearance
- Inappropriate lens alignment (lifting in periphery)

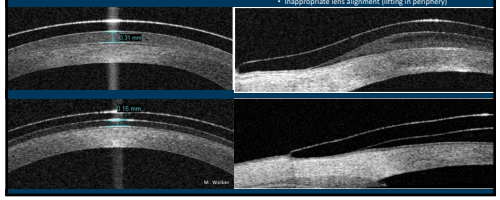

56

MIDDAY FOGGING

MULTIFACTORIAL

MANAGEMENT
- Switch to a fenestrated scleral lens
- Wash eye with an eyebath in the morning before lens application
- Scleral lens may be applied, removed, and reapplied to clear the eye of the morning gunk
- Use a more viscous solution for lens filling
- Use a balanced electrolyte solution for lens filling

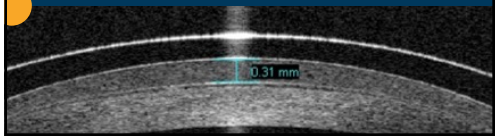

57

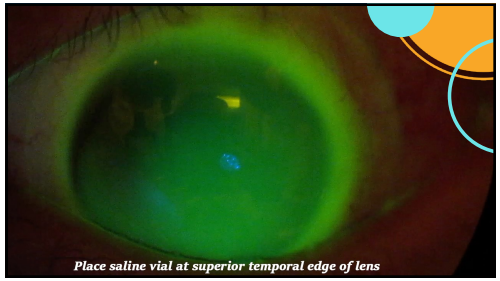

58

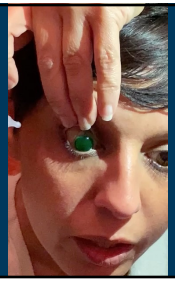

Spain

59



AGENDA

- Central — Touch corneal / Corneal Edema / Fogging
- Limbal — Limbus touch
- Landing — Blanching / Notches & Customization
- Centration — Prolapse conjunctiva / Lens decentration
- Surface and vision — Midday Fogging / Vision Problems

60

Visual problems

White fluffy particulate debris thought to be mucus in the tear reservoir

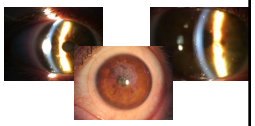

CAUSES

- Presence of **detritus & debris** in the post-lens fluid reservoir.
- Diffuse corneal punctate staining

Management

- Lens Fit:
  - Reduce central clearance or decrease the lens sagittal height
  - Asymmetric sclera: Improve the tangent alignment in both meridians
- Check and treat ocular causes (GPC, MGD, Blepharitis)
- Optimize lens solutions
- Use a more viscous solution for lens filling

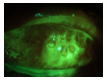

Giant papillary conjunctivitis

61

Visual problems

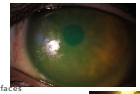

CAUSES

- **Lens Deposits** on external and internal lens surfaces
- Mucus, lipid or protein coating on lens surface
- Poor wettability

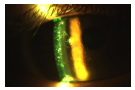

Management

- Treatment Ocular causes: GPC, MGD, Ocular allergy
- Insufficient lens care
  - Use a protein remover if the secretions consist of protein
  - Use a cleaner to avoid lipids and mucus and to improve wettability
- Apply cosmetics and cream only after lens insertion
- Replace the lens material if the cleaning system is not effective

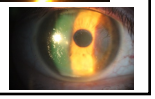

62

Visual problems

CAUSES

- Perform an over-refraction to identify any **remaining astigmatism**
- Lens instability:
  - Non-centered lens or rotation of a front toric

Management

- Internal astigmatism
  - Perform an over-refraction to identify any remaining astigmatism
  - Determine the position of the hash mark, order a front toric lens
- Lens instability
  - Check tangent alignment in both meridians
  - Increase the diameter

63

64